

ROP REACTIVATED!

Anisha Rathod, MD*(Corresponding Author)**Bombay Hospital and Research Institute Mumbai, India***Karobi Lahiri, PhD***Bombay Hospital and Research Institute Mumbai, India***Abstract:**

Purpose: To report a case of ROP reactivation, later in life following natural regression in infancy.

Methods: Prospective study focusing on ocular presentation and outcome of long term ROP follow-up at Tertiary Hospital, India. A 12-year-old female, seen by us first at 8 years of age, with a 6-monthly follow-up with known history of bilateral ROP came with complaints of black spots. The incident occurred after 4 years of follow-up in this patient at our center. On examination, patient had (OD) falciform fold at the macula and (OS) had regressed ROP. Left eye had developed new vascular buds (vessels) along avascular arcade. FFA was done and leaks with non-perfusion areas were noted. Patient didn't receive any treatment in the past and was on 6 monthly follow-ups.

Result: Based on the clinical symptoms and signs, reactivation of ROP was suspected and FFA examination revealed filling defects and leaks. After consent, laser therapy was given to stop the progression. Visual acuity and retina remained steady during the follow-up period. Bone densitometry done on patient showed low calcium levels.

Conclusion: Patients with history of ROP treatment with or without active signs should be evaluated lifelong to detect and avert vision threatening complications.

Keywords: ROP, Retinopathy of prematurity, retrolental fibroplasia

Case Reports

Preterm born, now 12-year-old female. Birth weight: 1.4 kg, Gestational age: 33-34 weeks. No other risk factors.

First ever eye examination at 6 months of age, On noticing strabismus in right eye OD- Falciform fold at macula (Figure .1) OS-Stage 4B junction of ZONE I and II (LE regressed ROP with fibrous proliferation) (Figure.2.) No treatment in the past. Screening was done at 2 prime institutes in past at 6 months of age. Child came to us at 8 years of age and was on a 6-monthly follow-up since then. At 12 years of age patient complained of black spots in the left eye. Examination there on revealed left eye had developed new vascular buds (vessels) along a vascular arcade and avascular junction. FFA was done and leaks from vascular buds with non-perfusion areas beyond the ridge were documented. FFA examination revealed filling defects and leaks. After consent, laser therapy was given to stop the progression. Visual acuity and retina remained steady during the follow-up period. Bone densitometry done on patient showed low calcium levels.

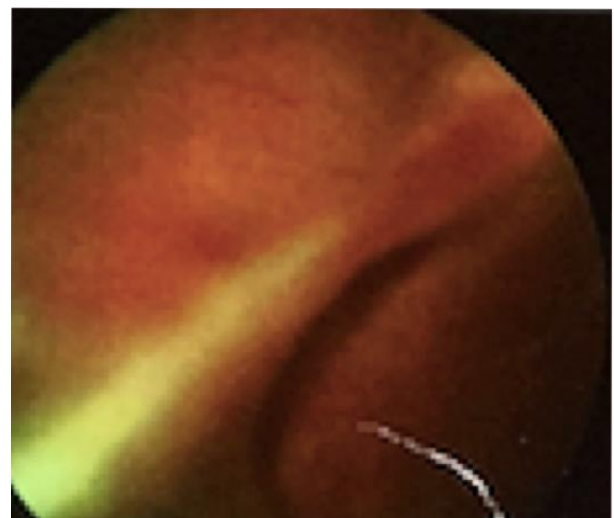


Figure.1. Right eye - Showing falciform fold at macula

Access this article online	
Quick Response Code:	Website: https://ophthalmolcases.com/index.php/hat
	DOI: 10.30546/2788-516X.2020.1.1.1
	

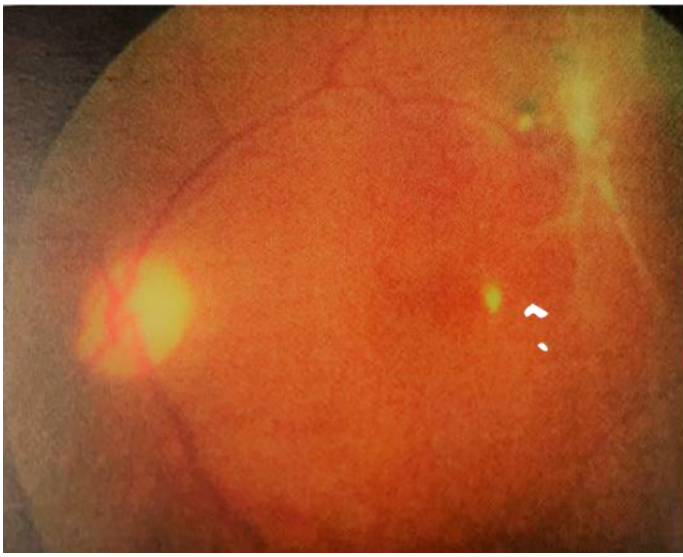

Figure 2. Left eye - Stage 4B junction of ZONE I and II (LE Regressed ROP with fibrous proliferation)

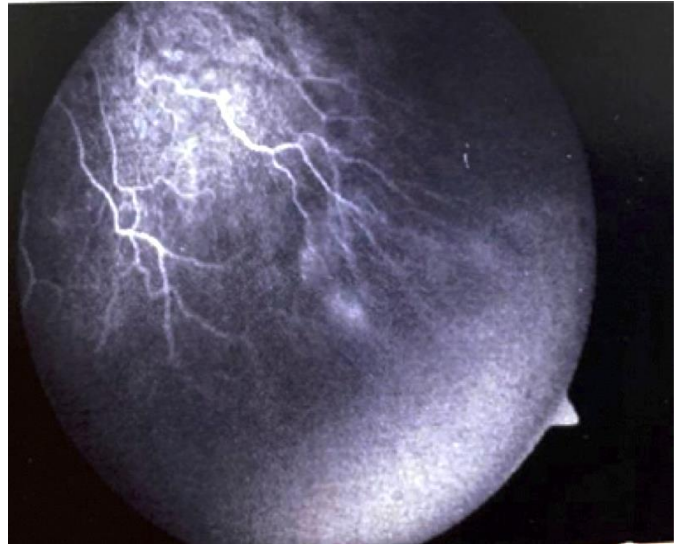


Figure .3/4. . Fundus fluorescein images showing leaks and pinpoint hyper fluorescent areas.

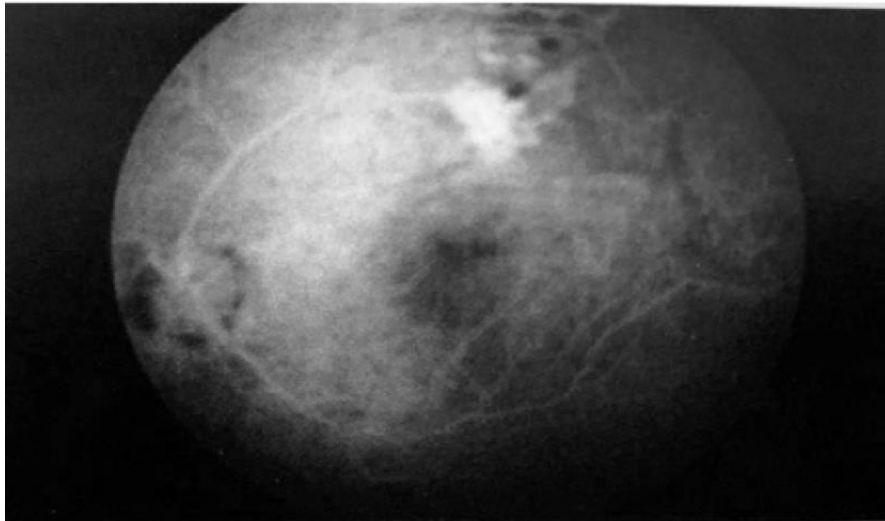


Figure. 4.

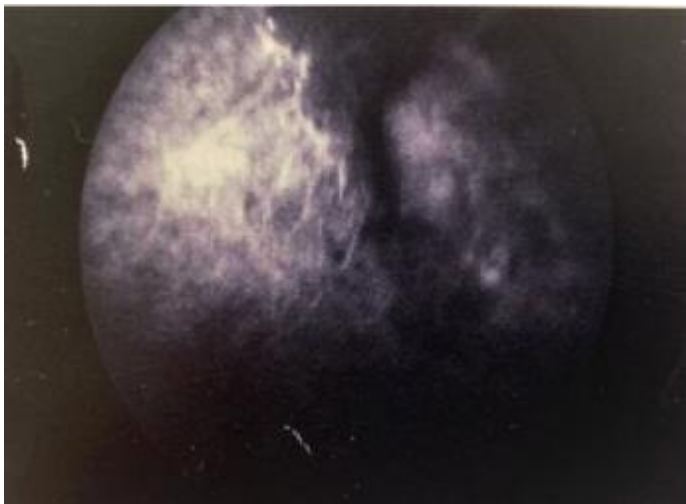


Figure.5/6. Fundus fluorescein pictures showing pin point areas of hyperfluorescence.

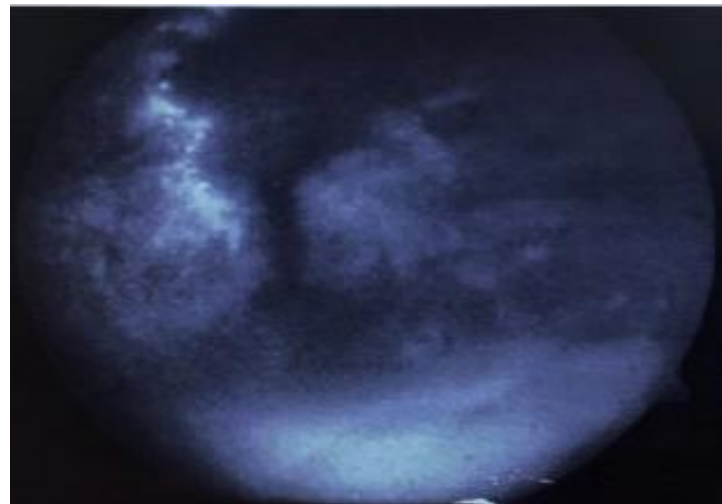

Figure.6.

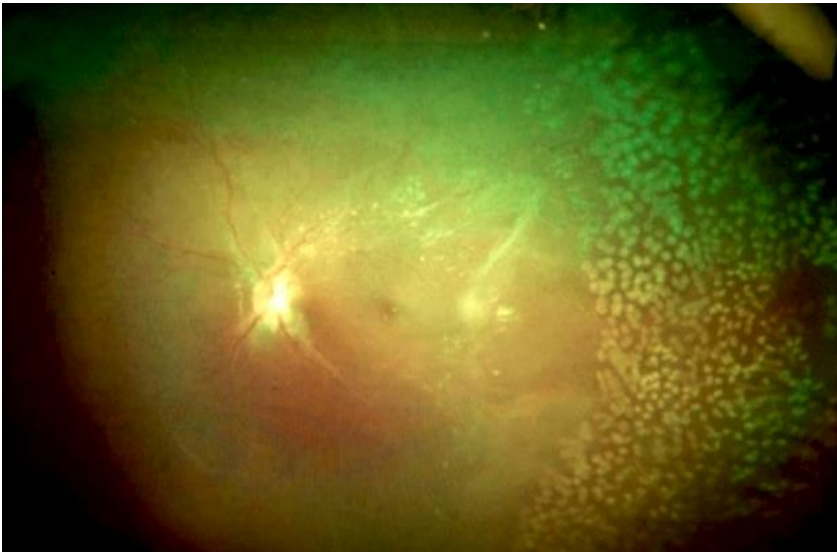


Figure 7. Picture showing post laser in case 1.

Parameters	Right eye	Left eye
Visual acuity	PL FC 2 feet	6/36 Corrected 6/18(p)
Anterior segment	Smaller eye	Cuneiform cataract
Refractive error	-8.00/-1.5 ax=144	-9.00/-0/75D ax=175
Ocular motility	Nystagmus Esotropia	Nystagmus

BONE DENSITOMETRY SCAN ADVISED

CASE HAS LOW CALCIUM DUE TO HYPOTHYROIDISM ON THYRONORM.

DISCUSSION: It is important to note that both FEVR and ROP were thought to show abrupt cessation of the capillary network with formation of scalloped border and leakage of fluorescein dye from this border. Angiographic findings included irregular sprouts of vascularization at the vascular/avascular junction, distinct pruning of vessels, pin-point areas of hyperfluorescence, and segmental areas of vascular leakage. The authors propose a classification of ROPER (ROP vs. FEVR) to more accurately stratify these patients. Identification of this subset of patients will allow for sustained surveillance of infants with ROPER who demonstrate a continuing risk of disease activity.1 Mrinal P. et al series describes clinical features in APVR in premature infants and suggests that early diagnosis and intervention may mitigate the typical aggressive course and poor prognosis of this condition.2 ROP can be considered a second class of disease involved in the FEVR-causing genes (i.e., multifactorial diseases). The fundus characteristics of eyes with ROP are similar to those of FEVR. Because of the phenotypic resemblance, genetic changes in the norrin/b-catenin signaling pathway are considered to be risk factors for advanced ROP. 3 Several studies have addressed this possibility, and the results showed that variants in the FZD4, LRP5 and NDP genes can account for 3-12% of eyes with ROP.3-6

Points for ROP

- History of prematurity
- Birth weight 1.4 kg
- No family history of FEVR
- No IVB (intravitreal bevacizumab) given.
- Gestational age 33-34 weeks

Discussion

The correct diagnosis of ROPER patients is important indistinguishing them from typical ROP, which does not characteristically progress. These infants need to be closely monitored for progression of disease early and often in their life, including serial angiography and treatment with laser, cryotherapy and anti-VEGF injections. Careful follow up of all cases especially the cases of regressed ROP or patients with faulty or incomplete vascularization on a lifelong basis so in conclusion it would be better to laser and throw away the dangling sword of uncertainty in case of probable faulty follow up. The vital question is do we laser every patient of regressed ROP test they do not maintain strict Long term follow-up?

Conflict of interests

The authors declare that there is no conflict of interests.

Data availability statement

The data that support the findings of this study are available from the corresponding author upon reasonable request.

Funding

None.

Study association

This study is not associated with any thesis or dissertation work

References

1. John VJ, McClintic JI, Hess DJ, Berocal AM. Retinopathy of prematurity versus familial exudative vitreoretinopathy: report on clinical and angiographic findings. *Ophthalmic Surg Lasers Imaging Retina* 2016; 47(1):14-19. doi: 10.3928/23258160-20151214-02
2. Gupta MP, Yonekawa Y, Campbel JP, Rusu I, Zahid S, et al. Early diagnosis and management of aggressive posterior vitreoretinopathy presenting in premature neonates. *Ophthalmic Surg Lasers Imaging Retina* 2019; (4):201-207. doi: 10.3928/23258160-20190401-01
3. Kondo H. Complex genetics of familial exudative vitreoretinopathy and related pediatric retinal detachments Taiwan J Ophthalmol 2015; 5(2):56-62. doi: 10.1016/j.tjo.2015.04.002
4. Holmstrom G, van Wijngaarden P, Coster DJ, Williams KA. Genetic susceptibility to retinopathy of prematurity: the evidence from clinical and experimental animal studies. *Br J Ophthalmol* 2007; 91(12): 1704-1708. doi: 10.1136/bjo.2007.117283
5. Bizaro MJ, Hussain N, Jonsson B, et al. Genetic susceptibility to retinopathy of prematurity. *Pediatrics* 2006; 118(5): 1858-1863. doi: 10.1542/peds.2006-1088
6. Shastri BS. Genetic susceptibility to advanced retinopathy of prematurity (ROP). *J Biomed Sci* 2010;17(1): 69. doi: 10.1186/1423-0127-17-69

How to cite this article: Rathod A., Lahiri K, *Rop reactivated* . *Ophthalmology Cases & Hypotheses*. 2020;01(01):1-4.