

DYNAMICS OF THE COURSE OF RETINITIS PIGMENTOSA IN A CHILD WITH MACULAR INVOLVEMENT OVER 6 YEARS.

Nushaba Hasan Nuri, MD

HATMedicine Clinic, Baku, Azerbaijan

Abstract:

Purpose: The purpose of this work was to describe retinitis pigmentosa involving the macula in a child with a follow-up of 6 years.

Methods: Case report.

Results: Over 6 years, the child exhibited an expansion of the lesion area of the central retina. On optical coherence tomography (OCT), there is a sharp thinning of the central region of the retina with pathology of the photoreceptor and pigment layers.

Conclusion: In some cases of retinitis pigmentosa, there are changes in the macula, characteristic of the dry form of macular degeneration; in other cases, there are cysts associated with cystoid macular oedema; and in other cases, there is a macular hole.

In our case, there was an atrophic lesion of the macula, characteristic of the dry form of age-related macular degeneration. Apparently, such involvement of the macula in the process is typical for children with early progression of the disease.

Keywords: *retinitis pigmentosa, retinitis pigmentosa accompanied by macular involvement*

Introduction

Retinitis pigmentosa (RP) is the most common form of hereditary retinal degeneration.^{1,2} RP comprises a heterogeneous group of inheritable disorders affecting photoreceptors and retinal pigment epithelium (RPE), which gradually leads to nyctalopia and visual field constriction. Typical features of RP include pigmentation (bony spicules), waxy optic disc pallor and arteriolar attenuation.³

The affected photoreceptors undergo apoptosis⁴, which is indicated by reduced outer nuclear layer thickness within the retina as well as in lesions and/or retinal pigment deposits in the fundus.

Macular changes have been shown to be associated with retinitis pigmentosa, although the incidence and possible origins of various lesions have not been fully described. The authors examined 31 patients with retinitis pigmentosa who had macular lesions and identified three categories of macular changes⁵.

The purpose of this work was to describe retinitis pigmentosa involving the macula in a child with a follow-up of 6 years.

Case Reports

A 5-year-old girl was referred to our clinic with complaints of poor vision and impaired night vision. The patient is the product of a second gestation with a birth weight of 2600 g. The parents of the patient are first cousins.

Her best corrected visual acuity (BCVA) was 0.3 in the right eye (RE) and 0.1 in the left eye (LE), with normal ocular motility. We used tropicamide 1% to achieve cycloplegic refraction. RE: +6.00/+1.00×96 LE: +5.00/+1.00×88

Slit lamp examination of the anterior segment and tonometry were normal. Indirect ophthalmoscopy revealed bilateral waxy pallor of the optic disc, narrowing of the arterioles and small accumulations of pigment in the periphery of the retina in the form of bony spicules, as well as loss of the foveal reflex with a small deposition of pigment, areas of depigmentation and atrophy of the retinal pigment epithelium (RPE).

[Figure. 1].

Thus, fundoscopic analysis of the right (A) and left (B) eyes shows abnormalities specific to retinitis pigmentosa.

Quick Response Code:	Website:
	https://ophthalmolcases.com/index.php/hat
	DOI: 10.30546/2788-516X.2021.2.1.1
	

Figure 1. Right eye and left eye of 5 eye-old-girl.

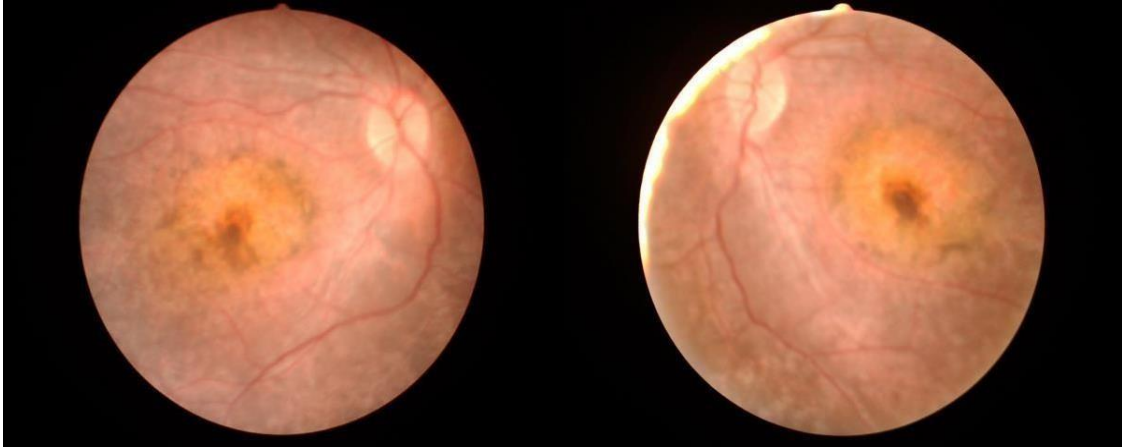



Figure 2. ERG showed a severe loss of both rod and cone signals



The examination of patient was carried out annually.

Examination of the patient after 6 years.

There was deterioration in visual acuity in both eyes, more on the left.

In the fundus, there was an increase in pigment deposits in the macular region in both eyes (Figure. 3) and in the left eye (Figure. 4). The fundus periphery of the left eye is shown in Figure 5. These changes are especially pronouncedly in the left eye. There is an extensive, rounded pigmented lesion. As a result, vision in both eyes has decreased.

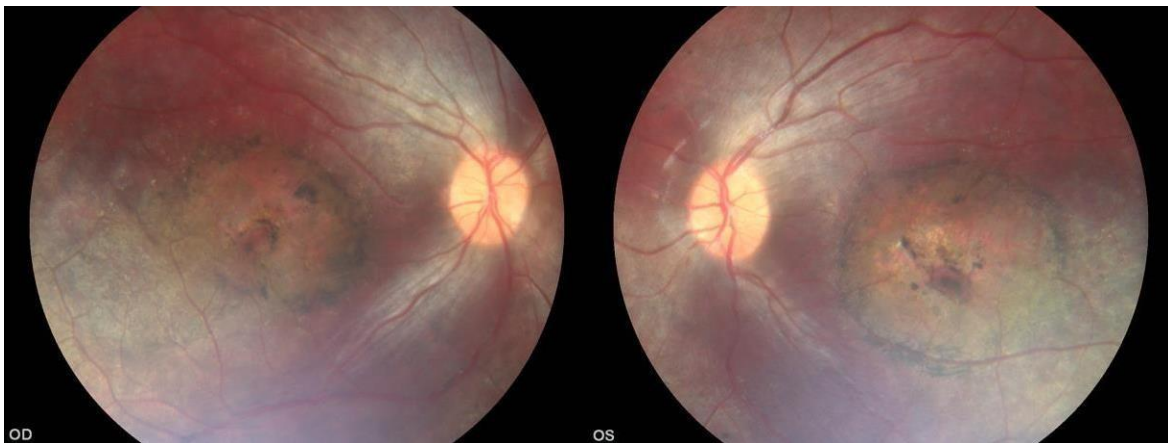


Figure 4. The fundus of the right and left eyes 6 years after the first examination.

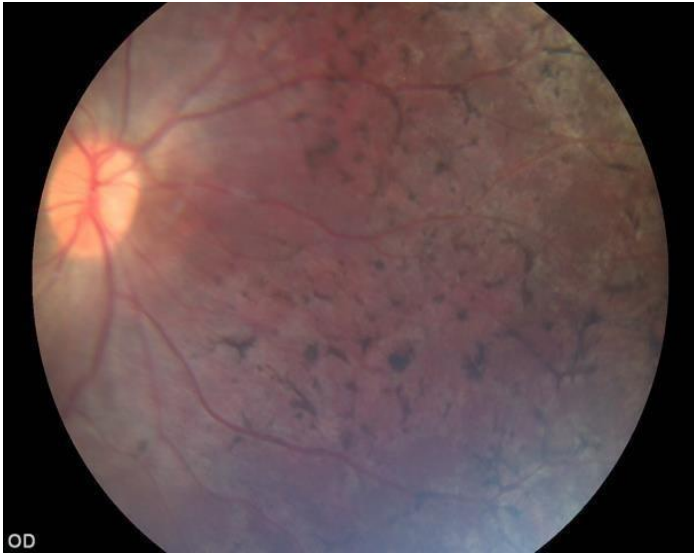
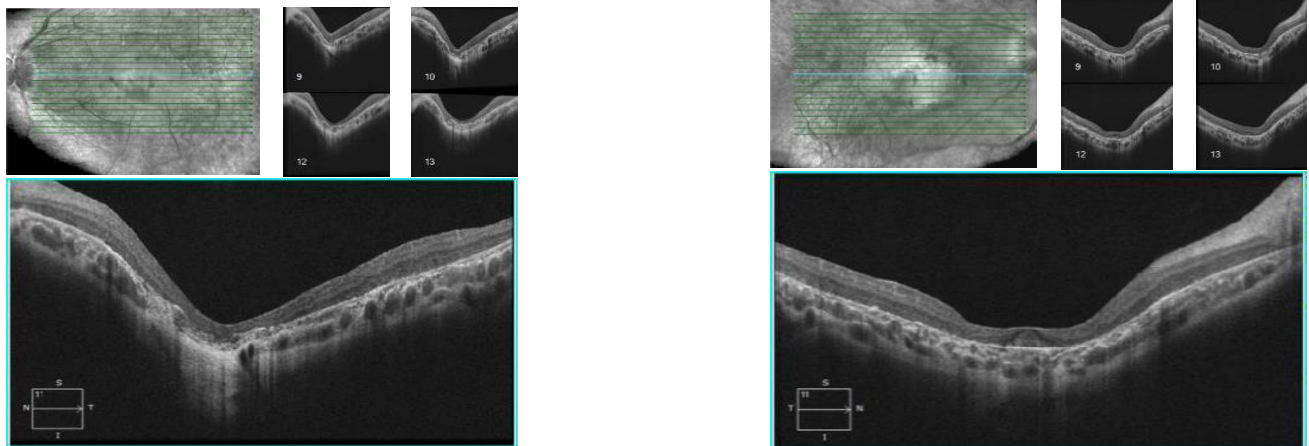


Figure. 5. The periphery of the fundus of the left eye.

On optical coherence tomography (OCT), there was a decrease in the thickness of the retina in the central zone, which was more substantial in the left eye (Figure 5). A decrease in the thickness of the central retinal zone is the main predictor of weak central vision.



*Figure. 4. Optical coherence tomography (OCT). Right eye (A) and left (B) eye with a decrease in the photoreceptors and macular atrophy of both eyes.
(Macular thickness is reduced, the photoreceptor line is undetectable, and the choroidal signal is enhanced. Hyperreflective punctate materials are visible)*

Discussion

Ten to twenty percent of patients with retinitis pigmentosa (RP) have been reported to have cystoid macular oedema (CME).⁶ This is important because CME can significantly reduce visual acuity in patients with RP whose vision is usually well preserved until the late stages of the disease. More recently, it was reported that the prevalence of CME detected by OCT in patients with RP was 38%.⁷

Other macular diseases, such as macular holes (MHs), epiretinal membranes (ERMs), and vitreomacular traction (VMT) syndrome, are less frequently detected in patients with RP. Giusti et al. (2002) examined 236 patients with RP ophthalmoscopically and found a macular hole in 25 patients.⁸

Our patient was diagnosed with retinitis pigmentosa with atrophic damage to the macula. Apparently, such involvement of the macula in the process is typical for children with early progression of the disease. Among patients with infantile or juvenile onset of retinal degeneration, the distinguishing features were the severity of visual loss and the age at onset of symptoms.

Conflict of interests

The authors declare that there is no conflict of interests.

Data availability statement

The data that support the findings of this study are available from the corresponding author upon reasonable request.

Funding

None.

Study association

This study is not associated with any thesis or dissertation work.

References

1. Pagon RA. Retinitis pigmentosa. *Surv Ophthalmol* 1988; 33: 137-77.
2. Berson EL. Retinitis pigmentosa: the Friedenwald lecture. *Invest Ophthalmol Vis Sci* 1993; 34:1659-1676.
3. Natarajan S. Retinitis pigmentosa: a brief overview *Indian J Ophthalmol* Sep-Oct 2011;59(5):343-6. doi: 10.4103/0301-4738.83608
4. Marigo V. Programmed cell death in retinal degeneration: targeting apoptosis in photoreceptors as potential therapy for retinal degeneration. *Cell Cycle* 2007;6(6):652–655. doi: 10.4161/cc.6.6.4029
5. Fishman GA, Fishman M, Maggiano J. Macular lesions associated with retinitis pigmentosa. *Arch Ophthalmol* 1977May;95(5):798-803. doi:10.1001/archophth.1977.04450050076006
6. Hagiwara A, Yamamoto S, Ogata K, Sugawara T, Hiramatsu A, et al. Macular abnormalities in patients with retinitis pigmentosa: prevalence on OCT examination and outcomes of vitreoretinal surgery *Acta Ophthalmol* 2011;89(2):122-125. doi: 10.1111/j.1755-3768.2010.01866.x.
7. Hajali M, Fishman GA. The prevalence of cystoid macular oedema on optical coherence tomography in retinitis pigmentosa patients without cystic changes on fundus examination *Eye* 2009; 23(4):915–919. doi: 10.1038/eye.2008.110.
8. Giusti C, Forte R, Vingolo EM Clinical pathogenesis of macular holes in patients affected by retinitis pigmentosa. *Eur Rev Med Pharmacol Sci* 2002; 6: 45–48. <https://www.europeanreview.org/wp/wp-content/uploads/7.pdf>

How to cite this article: Nuri, H.N. *Dynamics of the course of retinitis Pigmentosa in a child with Macular involvement over 6 years*. *Ophthalmology Cases & Hypotheses*. 2021;02(01):1-4.