

## MACULAR DETACHMENT IN MORNING GLORY SYNDROME

Ayan Mammadkhanova, MD

HAT Medicine Clinic, Baku, Azerbaijan

### Abstract

**Purpose:** The purpose of this study is to report a unique case of morning glory syndrome.

**Methods:** This study included ophthalmologic examination, optical coherence tomography and a review of the relevant literature.

**Result:** A 7-year-old girl with a history of morning glory syndrome was periodically examined in our clinic for 5 years. Suddenly, she presented with the complaint of decreased vision. Examinations revealed macular detachment. The visual field of the affected eye was significantly narrowed. OCT also revealed the presence of a fibrous cord in the centre of the optic nerve, which protruded into the vitreous body.

**Discussion:** Morning glory syndrome is an uncommon congenital disorder characterized by a widely enlarged papilla that is pink-orange in colour, with a small glial tuft in the centre. The retinal vessels are arranged radially in relation to the papilla. A pigmented ring surrounds the excavation. The incidence is not well known. The effect is generally unilateral. This syndrome manifests as optic atrophy. However, the atrophy does not progress. Visual impairment sometimes occurs when macular detachment arises, as occurred in our patient. After 5 years of observation, our patient's vision dramatically worsened as a result of macular detachment. There are various theories for the development of macular detachment in MGS: exudative, traction and rhegmatogenous<sup>8</sup>. No break was found in our patient, so the cause of the detachment was most likely the inflammatory process

**Keywords:** Macular detachment, morning glory anomaly.

### Introduction

Morning glory disc anomaly (MGDA) is a rare congenital malformation that results from incomplete formation of the optic nerve *in utero*.<sup>1</sup> This anomaly was termed "morning glory syndrome" because of its resemblance to the tropical flower. In MGDA, the optic disc is usually enlarged, is orange or pink in colour, and has a funnel-shaped excavation surrounded by a pigmentary border that is usually raised.

Whitish glial tissue is present at the bottom of the disc, representing an important criterion for diagnosing the syndrome. The retinal blood vessels emerge from the periphery of the excavation in a radial pattern. The macula may be incorporated into the excavated defect (macular capture).<sup>2</sup>

MGS may be associated with ocular and systemic abnormalities. Retinal detachment (RD) is one of them. It is a severe complication of MGS, with a high incidence (26–38%).<sup>3</sup>

### Case Reports

A 7-year-old girl with a history of morning glory syndrome presented to our clinic with the complaint of significantly decreased vision of her right eye. Before that, the child had been periodically examined in our clinic over 5 years. The patient's systemic examination was unremarkable. She had been wearing glasses for one year.

The patient's previous observation revealed a best corrected visual acuity (BCVA) of 20/100 in the right eye (OD) and 20/20 in the left eye (OS) using Snellen's chart. Her cycloplegic refraction was OD -6.0 diopteric spherical (DS), -4.0 diopteric cylindrical (DC) × 178°; OS -2.75DS, -4.0DC × 171°.

The patient's intraocular pressure was normal in both eyes. Slit-lamp examination was not contributory. The right pupil had a diameter of 3 mm and an afferent pupillary defect.

Fundus examination of the right eye showed a large, excavated disc covered by translucent glial tissue [Figure. 1] and peripapillary chorioretinal pigmentary changes. Retinal

Access this article online	
Quick Response Code:	Website: <a href="https://ophthalmolcases.com/index.php/hat">https://ophthalmolcases.com/index.php/hat</a>
	DOI: 10.30546/2788-516X.2021.2.1.13
	

vessels fanned out from the disc in a radial fashion. The foveal reflex was dull with no involvement of the macula in the excavation, and the peripheral retina was intact without suggestion of retinal detachment. The fundus of the left eye was unremarkable.

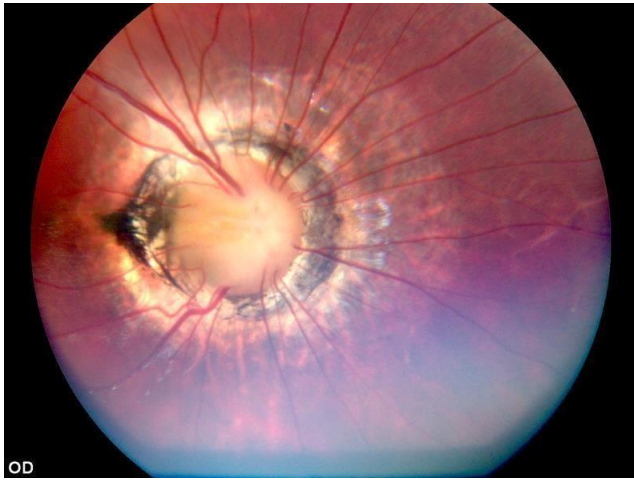


Figure. 1. Fundus examination (right eye) showed a large, excavated disc with retinal vessels radiating from the periphery and a tuft of translucent fibrous tissue covering the central part of the excavation

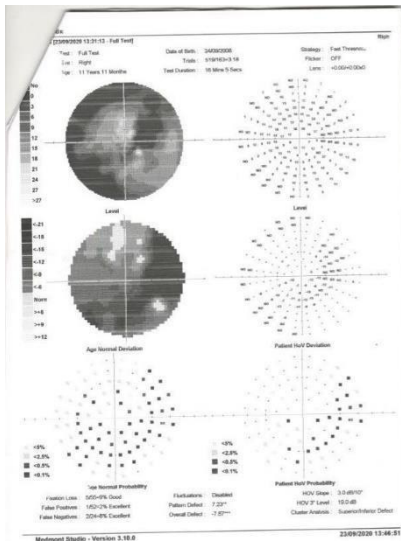
B-scan ultrasonography showed a conoid-shaped anomalous excavation with the disc at the base of the posterior pole in the right eye. The scan of the posterior pole was normal.

Typical echographic changes confirmed the diagnosis of morning glory syndrome. The brain scan was normal. An MRI of the orbit showed no posterior staphyloma.

The last observation of the patient revealed a BCVA of 20/500 in the right eye and 20/20 in the left eye. There were no fundus changes in comparison with that at the previous examination.

Visual field testing with a Medmont perimeter demonstrated that the visual field of the right eye was significantly narrowed [Figure. 2]. The left eye was within normal limits.

Figure. 2. The Medmont visual field showed a pronounced diffuse reduction in retinal sensitivity in the right eye.



Spectral-domain optical coherence tomography (SD-OCT) images of the optic disc of the right eye showed a centrally excavated enlarged disc with an enlarged cup-disk ratio and loss of neuroretinal rim with reduced retinal nerve fibre layer thickness in the superior, nasal and temporal quadrants [Figure. 3].

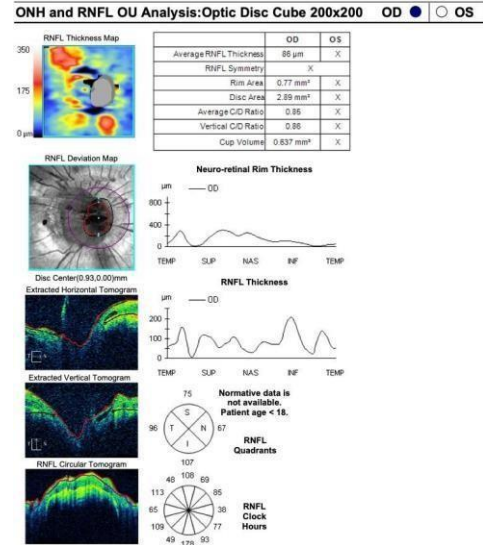


Figure. 3. Cirrus HD-OCT RE shows a centrally excavated disc with an enlarged C:D ratio and reduced retinal nerve fibre layer thickness. In the centre, there is a fibrous cord, which protrudes into the vitreous body.

A three-dimensional reconstructed view of the optic disc cube showed a central conoid excavated optic disc [Figure. 4]. There is a fibrous cord in the centre that protrudes into the vitreous body and resembles the pistil of a flower.

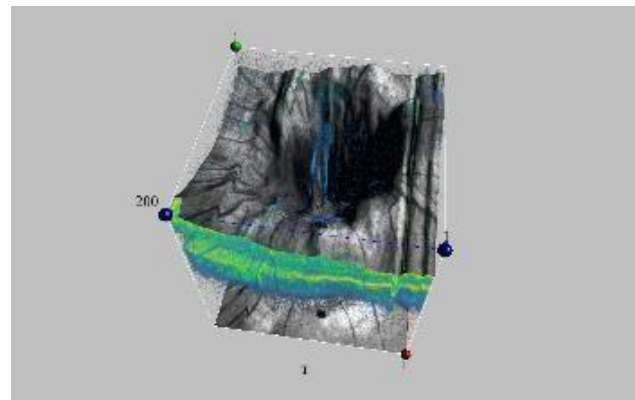
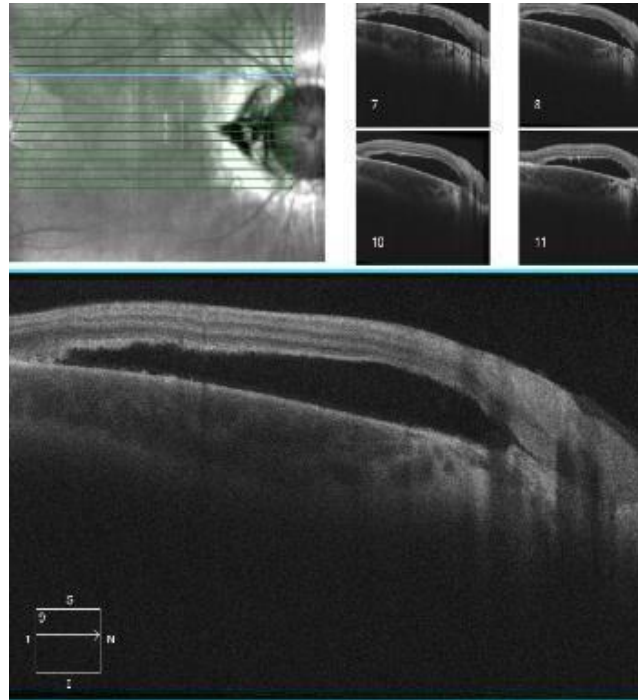


Figure. 4. A fibrous cord in the centre of the optic disc protrudes into the vitreous body. It resembles the pistil of a flower.

OCT demonstrated sub-macular fluid and neurosensory retinal detachment adjacent to the morning glory disk [Figure. 5]. No break was found. It appears that the patient's reduced vision is associated with this detachment.

The patient's parents were offered the opportunity for the patient to have surgery to correct the detachment, but they declined.

Figure. 5. Ocular coherence tomography confirms OD macular neurosensory detachment.



## Discussion

MGS is a congenital, non-hereditary and usually unilateral optic nerve disease. It is characterized by an enlarged, funnel-shaped, sometimes excavated optic disc with a central mass of whitish-grey glial tuft and a disc with scleral staphyloma, which may be surrounded by a raised, white or pigmented peripapillary ring; the blood vessels are increased in number and emanate radially from the disc.<sup>4</sup>

The aetiology and embryogenesis of MGS is poorly understood. MGS is diagnosed fairly early, as in our case. Such patients often have low visual acuity. Facial and central nervous system abnormalities can be associated with MGS. Our patient's brain scan results were normal. MGS may also be accompanied by ocular abnormalities such as strabismus, nystagmus, cataracts, aniridia, lens coloboma, eyelid haemangioma, microphthalmos, retinal detachment<sup>5</sup> (30% of cases) and, rarely, choroidal neovascularization.<sup>6</sup>

MGS should be differentiated from other congenital optic disc anomalies, such as optic disc coloboma and

peripapillary staphyloma. Typical optic disc coloboma is bilateral and presents as a central crater that may resemble glaucomatous cupping. In peripapillary staphyloma, there is developmental weakness of the posterior sclera leading to stretching of the choroid and exposure of the sclera with a relatively normal-appearing sunken optic disc below the surrounding retinal level.

As a result of variable presentation, various ocular investigations, such as B-scan, OCT and FFA, are helpful not only in confirming the diagnosis but also in the early detection of complications. This case report shows an enlarged optic disc and cup with thinning of the RNFL and normal macular thickness. OCT plays a significant role in the early diagnosis and evaluation of possible sub-retinal fluid, thus providing information regarding the pathogenesis and associated clinical features.<sup>7</sup>

Interestingly, in the centre of the optic nerve head of our patient, there is a vertical cord that penetrates the vitreous body, similar to a pistil, thus resembling a flower and highlighting the suitability of the name of MGS. The strongest attachment of the disc to the vitreous body is located in the central part of the optic nerve.

MGS manifests as optic atrophy. However, the atrophy does not progress. Visual impairment sometimes occurs when macular detachment occurs, as occurred in our patient. After 5 years of observation, our patient's vision dramatically worsened as a result of macular detachment.

There are various theories for the development of macular detachment in MGS: exudative, traction and rhegmatogenous.<sup>8</sup> No break was found in our patient, so the cause of the detachment was most likely the inflammatory process.

Considering the above, children diagnosed with MGS should be monitored constantly, as immediate intervention is sometimes critical.

### **Conflict of interests**

The author declares that there is no conflict of interests.

### **Data availability statement**

The data that support the findings of this study are available from the corresponding author upon reasonable request.

### **Funding**

None.

### **Study association**

This study is not associated with any thesis or dissertation work.

## References

1. Magrath GN, Cheeseman EW, Sarrica RA. Morning glory disc anomaly. *Pediatr Neurol* 2013;49:517 DOI: 10.1016/j.pediatrneurol.2013.05.015.
2. Dua P., Amar Dev A., MS, Akash Dua A. Isolated sporadic Morning Glory syndrome arare entity. *Del JOphthalmol* 2012;22(3):207-208.
3. Lytvynchuk LM, Glittenberg CG, Siamak Ansari-Shahrezaei S. Binder S. Intraoperative optical coherence tomography assisted analysis of pars Plana vitrectomy for retinal detachment in morning glory syndrome: a case report. *BMC Ophthalmology* 2017; 17(1):134 DOI 10.1186/s12886-017-0533-0.
4. Willem A Manschot. Morning glory syndrome: a histopathological study. *British Journal of Ophthalmology* 1990,74: 56-58. DOI: 10.1136/bjo.74.1.56
5. Yang XL, Zhang X. Vitrectomy of rhegmatogenous retinal detachment in morningglory syndrome. *Int J Ophthalmol* 2010;3(1):89-91. doi: 10.3980/j.issn.2222- 3959.2010.01.21
6. Dos Santos Martins TG, dos Santos Martins DG, de Azevedo Costa ALF. Einstein (SanPaulo) Patient with Morning Glory syndrome. July 3, 2015;13(1):165-166 DOI: 10.1590/S1679-

**How to cite this article:** Mammadkhanova.A, *Macular detachment in morning glory syndrome.* *Ophthalmology Cases & Hypotheses.* 2021;02/01:13-17.