

ESOTROPIA WITH ECCENTRIC FIXATION LOCATION. CASE REPORT OF AN 11-YEAR FOLLOW-UP STUDY.

Narmina R. Hajiyeva MD, Ph.D

National Ophthalmology Center named after the Academician Zarifa Aliyeva, Baku, Azerbaijan

Abstract

Purpose: The purpose of this study is to report, how a small degree of anisometropia can lead to esotropia and low visual acuity in the case of delayed treatment.

Methods: This study included orthoptic examination with the alternate prism cover test, anterior segment assessment using a slit lamp, fundus examination, cycloplegic retinoscopy and autorefractometry.

Results: In a case of esotropia that presented from early childhood, the cause was determined to be amblyopia associated with astigmatic microanisometropia.

Conclusion: Refraction in children should be checked as early as possible (at 3 months) to detect anisometropia and correct it in a timely manner. This can lead to the disappearance of concomitant strabismus in the human population.

Keywords: *esotropia, eccentric fixation, strabismus, anisometropic amblyopia.*

Introduction

Strabismus is a common childhood disorder that causes the deviation or squinting of the eyes. If left untreated, it can permanently affect vision and can have an irreversible effect on the personality and mindset of a child.^{1,2}

Esotropia often manifests itself in early childhood. Due to the early onset and permanent nature of esotropia, binocular vision is impaired, often accompanied by amblyopia and impaired stereopsis³. Some patients have eccentric fixation. Eccentric fixation has been reported by Cüppers (1958) and Von Noorden (1970) to exist in as many as 35% to 44% of cases of amblyopia and thus constitutes a considerable factor in the management of this condition⁴.

Our studies have previously shown that the main cause of strabismus is manifest or latent anisometropia.^{5,6}

Case Reports

In 2010, a 7-year-old boy presented with inward deviation of the left eye from 3 months from the date of birth. He had esotropia of 45 prism diopters (PD) of left eye. On the alternate prism cover test for distance, there was an esotropia of 30 prism dioptres (PD) in the primary position in the left eye. The patient was otherwise healthy and neurologically normal. No family history of strabismus, amblyopia, or myopia was reported.

Unfortunately, we did not take a photo of the eye position at that time.

His uncorrected visual acuity (UCVA) was 20/25 in right eye and 20/200 in left eye. Cycloplegic refraction with 1% atropine was checked by means of autorefractometry: right eye (RE) spherical diopter (SD) +1.0, cylindrical diopter (CD) + 0.75 ax 86 ; left eye (LE) SD +1.5, CD + 1.0 ax 93 (Figure 1) and retinoscopy: OD SD + 1.5, CD +0.5; OS SD +3.0, CD +1.0.

Quick Response Code:	Website: https://ophthalmolcases.com/index.php/hat
	DOI: 10.30546/2788-516X.2021.2.2.1
	

DATE: 2010.06.24 10:08
Exam. No.: 000020

<RIGHT>
[REF VD=12.0mm]

SPH	CYL	AXIS	
+1.00	+0.75	88	0
+1.00	+0.75	86	0
+1.00	+0.75	87	0
+0.75	+0.75	85	0
+0.75	+0.75	83	0
+1.00	+0.75	84	0
+0.75	+0.75	86	>

<LEFT>
[REF VD=12.0mm]

SPH	CYL	AXIS	
+1.25	+1.25	93	0
+1.25	+1.25	93	0
+1.50	+1.25	94	0
+1.50	+1.25	93	0
+1.50	+1.00	92	0
+1.75	+0.75	88	0
+1.50	+1.00	90	0
+0.75	+1.25	99	0
+0.75	+1.25	102	0
+0.50	+1.00	88	0
+0.75	+0.75	88	0
+1.25	+1.00	93	>

Figure 1. Refractive data for 2010.

Retinoscopy and refractometry data of the right eye were approximately the same.

Retinoscopy showed a greater hyperopic refraction in the left eye. We believe that the retinoscopy data are more accurate, which was reflected in the glass prescription.

The patient had anisometropic and strabismus amblyopia, which was confirmed by a study of visual evoked potentials (VEPs) (Figure 2).

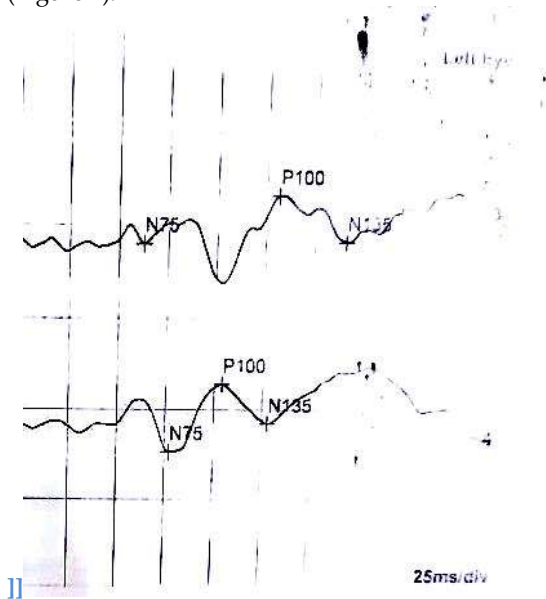


Figure 2. VEPs showed normal latency of N75 and P100, but the amplitudes of N75 and P100 in the left eye were moderately decreased.

Slit lamp examination of the anterior segment and dilated fundus examination were unremarkable in both eyes.

An evaluation of the fixation location revealed that the left eye

had an eccentric (or cecentral) fixation location. Star fixed by an area more than 4° from the fovea but not around the disc.

Glasses were prescribed for the possible reduction of strabismus. Prescribed glasses: RE CD +0.5 ax 85; LE SD +1.0, CD +1.0 ax 93. Six months after the first examination and wearing glasses, the eyes reached an almost symmetrical position. We examined the child every 6 months over 10 years.

In 2015, in the primary gaze position, the eyes were in an almost symmetrical position. UCVA was 20/20, in right eye and 20/200 in left eye. Cycloplegic refraction with 1% atropine was by autorefractometry RE SD +0.5, CD +0.5 ax 70; LE SD -0.5, CD +0.75 ax 83 (Figure 3) and by retinoscopy RE Sph +1.0, LE Sph +1.0 Cyl +0.5.

02/Feb/2015 10:36:43

RIGHT
[REF VD=12.0mm]

SPH	CYL	AXIS	
+0.50	+0.50	70	0
+0.25	+0.75	71	0
+0.50	+0.50	69	0
+0.50	+0.5	70	>

SE 10.75 D

LEFT
[REF VD=12.0mm]

SPH	CYL	AXIS	
-0.5	+0.5	80	
+0.75	+0.75	83	

Figure 3. Cycloplegic refraction of the patient in 2015.

There was a decrease in both the spherical and cylindrical components of refraction in both eyes. New glasses were prescribed taking into account the new correction.

In 2021, in the primary gaze position, the eyes were almost symmetrical (Figure 4). The patient has not worn glasses for a year.

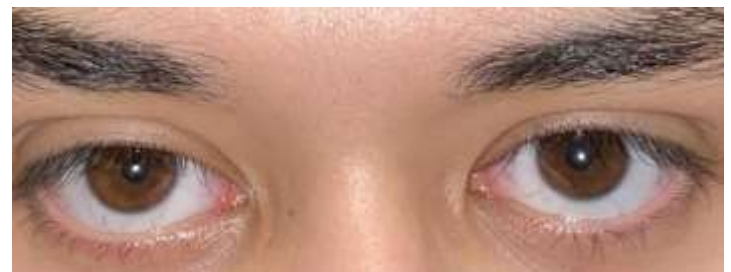

Figure 4. The eyes in symmetrical position.

His UCVA 20/20, in right eye and 20/200 in left eye. Autorefractometry: OD SD +0.25, CD - 0.5 ax 164 ; OS SD 0 CD + 0.75 ax 85 (Figure 5), retinoscopy: OD SD + 1.0. CD 0, OS SD +1.0, CD +0.5.




Figure 5. Cycloplegic refraction of the patient in 2021.

The patient has no indication for glasses at this time. Prescription glasses for astigmatism correction for the left eye do not improve visual acuity. However, the patient asked for glasses prescription. He said that he felt more comfortable with them, and we have prescribed him glasses. RE Planum, LE CD + 0.75 ax 85.

Discussion

This example shows how a small degree of anisometropia can lead to esotropia. If the parents of the child had taken him to an ophthalmologist when he was 3 or 5 months old, then the prescription glasses would have completely eliminated strabismus and amblyopia. In young children, we use three types of hand-held refractometers and retinoscopy to accurately determine refraction. At the age of 7 years, it is impossible to correct the fixation. Nevertheless, we prescribed glasses for the child at this age to reduce the angle of strabismus. The strabismus angle gradually decreased and almost completely disappeared. There was no need for the surgery. However, the spectacles did not lead to an improvement in the visual acuity of the left eye. This 7-year-old child had both spherical and astigmatic anisometropia. Spherical refraction detected with retinoscopy was slightly higher than that detected with autorefractometry. In children, we do not prescribe a complete correction of hyperopia. The main treatment goal is to correct the cylindrical refractive component. The spherical hyperopic

component of refraction in 3.0 D is critical. Up to 3.0 D, the child can, with the help of accommodation, bring focus to the retina. If hypermetropia is more than 3.0 D, the image on the retina will be blurry, and fusion will not occur. The same goes for the astigmatic component. Apparently, at birth, the degree of hyperopia in our patient was even higher.

Over 11 years of observation, we observed a decrease in both the degree of hyperopia and the degree of astigmatism. Anisometropia decreases with age, and if refraction is found at a late visit to the ophthalmologist, it is difficult to imagine that microanisometropia is the cause of the development of esotropia.

Therefore, refraction in children should be checked as early as possible (at 3 months) to detect anisometropia and correct it in a timely manner. This can lead to the disappearance of concomitant strabismus in the human population.

Conflict of interests

The author declares that there is no conflict of interests.

Data availability statement

The data that support the findings of this study are available from the corresponding author upon reasonable request.

Funding

None.

Study association

This study is not associated with any thesis or dissertation work.

References and notes:

1. Mohny BG. Common forms of childhood esotropia. *Ophthalmology* 2001 Apr;108(4):805-9. DOI: 10.1016/s0161-6420(00)00639-4
2. Mohny BG. Common forms of childhood strabismus in an incidence cohort. *Am J Ophthalmol* 2007;144(3):465-7.. DOI: 10.1016/j.ajo.2007.06.011
3. Simonsz H., Elikemans M Predictive value of age, angle, and refraction on rate of reoperation and rate of spontaneous resolution in infantile esotropia//*Strabismus* 2019;18(3):87-97
4. von Noorden GK. Etiology and pathogenesis of fixation anomalies in strabismus. I. Relationship between eccentric fixation and anomalous retinal correspondence. *Am J Ophthalmol* 1970;69(2):210-222
5. Kasimov E.M., Gadzhieva N.R. The Influence of the complete correction of refractive anomalies on the outcome of the treatment of esotropia in the children at the age of up to 3 years. *Rossiyskaya pedeatricheskaya oftalmologiya* 2015;4:8-11.
(<https://cyberleninka.ru/article/n/vliyanie-polnoy-korreksii-anomaliy-refraktsii-na-ishod-lecheniya-ezotropii-u-detey-v-vozraste-do-3-h-let/viewer>)
6. Hajiyeva N.R. On the role of micro anisometropia (the “batterfly” effect) in the occurrence of esotropia in children. *Ophthalmology Cases and Hypotheses* 2020;1(1):14-17. DOI: 10.30546/2788-516X.2020.1.1.14

How to cite this article: Hajiyeva N.R. Esotropia with eccentric fixation location. Case report of an 11-year study *Ophthalmology Cases & Hypotheses*. 2021;02(02):1-4.