

ACUTE ZONAL OCCULT OUTER RETINOPATHY (AZOOR) PROGRESSION: 30- YEAR FOLLOW-UP OF A CLINICAL CASE

Hajiyev R.V. MD, PhD.

Department of Ophthalmology, Azerbaijan State Advanced
Training Institute for Doctors named after A.Aliyev (ASATID),
Baku, Azerbaijan

Abstract

Purpose: The purpose of this study is to report a 30-year follow-up of a clinical case with progressive acute zonal occult outer retinopathy (AZOOR).



Methods: This study included an ophthalmic examination, optical coherence tomography (OCT), visual field studies, an electroretinogram (ERG) investigation, and a review of the relevant literature.

Results: A 34-year-old woman presented with a central scotoma in her right eye that had lasted for 5 months and a similar complaint in her left eye for a week. Changes in the fundus were minimal. The diagnosis was difficult. Later, as a result of the detection of a pronounced change in the ERG, local narrowing of the visual field (VF) and other symptoms, it was possible to make a diagnosis of AZOOR. We treated this patient first with parabolbar injections of dexamethasone and then with intramuscular ceftriaxone and intravenous dexamethasone. This treatment has had a stable positive effect.

Conclusion: AZOOR occurs suddenly, most often in women. Initially, minimal retinal changes are characteristic of this disease, accompanied by clearly defined areas of retinal dystrophy. There is a local narrowing of the visual field and a decrease in the amplitude of the ERG.

The difference between this disease and other diseases accompanied by a decrease in ERG is the good response to systemic corticosteroids (parabolbar or intravenous dexamethasone). The difference between this disease and other diseases accompanied by a decrease in ERG is the good response to systemic corticosteroids (parabolbar or intravenous dexamethasone). This disease is characterized by periodic exacerbations and gradual progression. After 30 years of observation of the present case, there was a significant decrease in visual acuity (VA) and the visual field (VF) and almost total retinal dystrophy, with the reduced ERG.

Keywords: Acute zonal occult outer retinopathy (AZOOR), electroretinogram (ERG), visual field (VF).

Access this article online	
Quick Response Code:	Website: https://ophthalmolcases.com/index.php/hat
	DOI: 10.30546/2788-516X.2022.3.1.4
	

Introduction

Acute zonal occult outer retinopathy (AZOOR) is an ocular syndrome characterized by an acute decrease in outer retinal function in one or more retinal zones, initially minimal or no funduscopic changes, enlarged blind spots, reduced outer retinal function measured by electroretinography in one or both eyes, and permanent visual field (VF) loss that is often associated with slow-progressing degeneration of retinal pigment epithelial (RPE) cells (1).

It tends to occur in young women and is usually associated with photopsia. Sometimes it occurs in men (2).

Its electrophysiological abnormalities include reduced full-field electroretinograms (ERGs), especially in the a-wave, and reduced early receptor potentials (ERPs) during the acute and vision-impaired phases of the disease (3,4).

The aetiology of AZOOR is unknown, but some aetiological studies have suggested the possibility that viral or fungal infections or autoimmune diseases may cause AZOOR (5,6).

Case Reports

We observed this clinical case in 1990. A 34-year-old female presented with central scotoma of 5 months' duration in the right eye and a similar complaint in the left eye for a week. Prior to that, she was treated in another clinic for an unknown presentation with antibiotics. They had no effect, but rather her vision worsened. The best-corrected visual acuity (BCVA) was 20/100 in the right eye and 20/32 in the left eye. Her past history was unremarkable. Her parents were cousins.

Fundus examination revealed a circumscribed, flat, peripapillary, deep retinal lesion with a greyish, marginal opacification or demarcation line in both eyes. There was a clear boundary between the normal retina and the pathological retina.

On the pathological zone, a pronounced "parquet" type of fundus was noted, without signs of pigment. The fundus photograph showed minimal changes. Unfortunately, there are no images of the fundus left in our archive.

The colour of the optic disc was normal, with clear boundaries. Blood vessels showed no abnormalities.

Near the optic nerve head in a photograph taken in 2010 (Figures 1, 2), a clear border between the affected and healthy tissue was marked with a red circle (Figure 1).

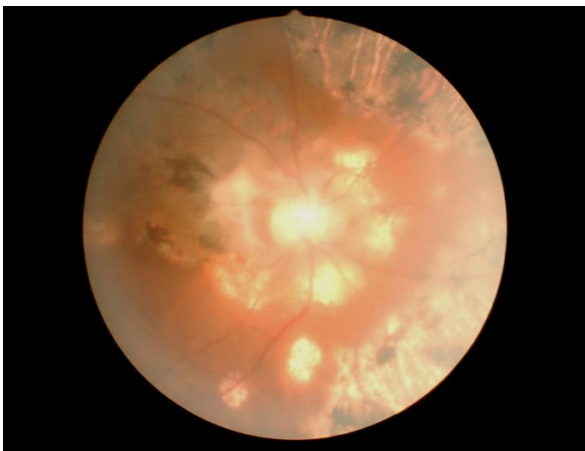

Figure 1. Right eye 2010 year. In the red circle, a clear border between damaged tissue and normal tissue is visible. There is a significant increase in the area of deep damage to the retina. In these places, lumps of pigment are noted. There is also blanching of the optic nerve head.

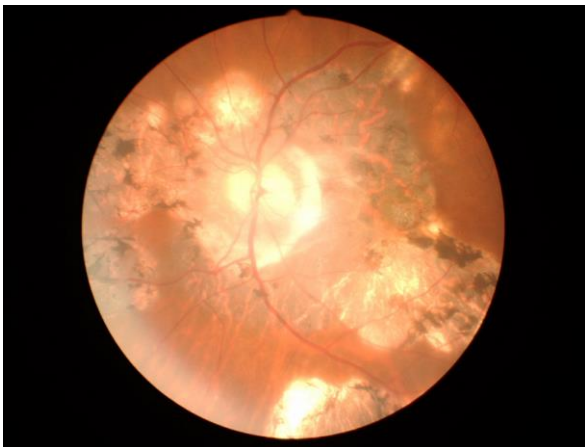

Figure 2. Left eye 2010 year

Before that, during the initial examination, we saw such a picture only in a small area of the retina, without pigment deposits.

The field of vision was narrowed in both eyes. At that time, ERG was not done.

We had difficulty making a diagnosis. Since her vision deteriorated suddenly, we speculated that it could be inflammation.

A provisional diagnosis of retrobulbar neuritis was made. We were puzzled by small areas of dystrophy on the retina, clearly defined, similar to the "parquet" type in myopia, but clearly demarcated from the rest of the retina. We were unable to make a confident diagnosis. Since she received antibiotics at another clinic, which made her worse, we decided to give her only peribulbar injections of dexamethasone. Her visual acuity improved immediately.

Within a week, her BCVA improved to 20/50 in the right eye and to 20/25 in the left eye, and the patient was very satisfied. The patient periodically, when there was deterioration, at first every 6 months and then once a year, came to us. First, we gave her parabolbar dexamethasone, then systemic dexamethasone (4 mg/1 ml intravenous), and each time her eyes improved and her visual acuity increased. VA remained within 20/50 for several years.

Then it dropped to 20/63. Interestingly, each time after taking steroids, VA rose, and long-term remission was observed. At each subsequent examination, a slight increase in the area of retinal damage was observed in the fundus. Then pigment spots began to appear in these places.

Unfortunately, from 2000 to 2010, the patient did not contact us, and we did not see her.

The next examination was carried out in 2010. We were amazed, as her BCVA in both eyes was 0.06.

There was a significant expansion of the area of the lesion, and pigment deposits had appeared, resembling pigmentary retinitis. It is known that retinitis pigmentosa is a hereditary disease that is accompanied by hemeralopia (which the patient did not have at first), as well as a gradual decrease in vision.

The deterioration in vision of the patient increased suddenly before she came to us each time, and then her vision improved to 0.08 after the use of corticosteroids. This is usually not seen in retinitis pigmentosa.

Only in 1993 did Gass (1993) describe a new disease, which he named AZOOR. In 2010, having synthesized the anamnesis and all the data, we diagnosed the patient with AZOOR. The next time the patient contacted us in 2014. Her VA was 0.06 in both eyes (Figures 3,4).

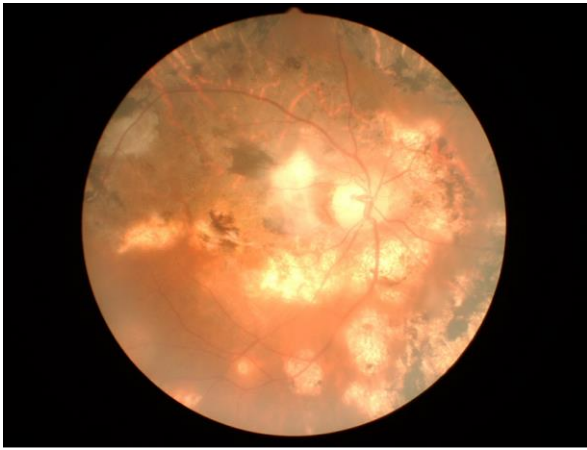


Figure 3. Fundus photos of the right and left eyes in 2014. There is an even greater increase in the area of deep damage to the retina, there are much more pigment spots.

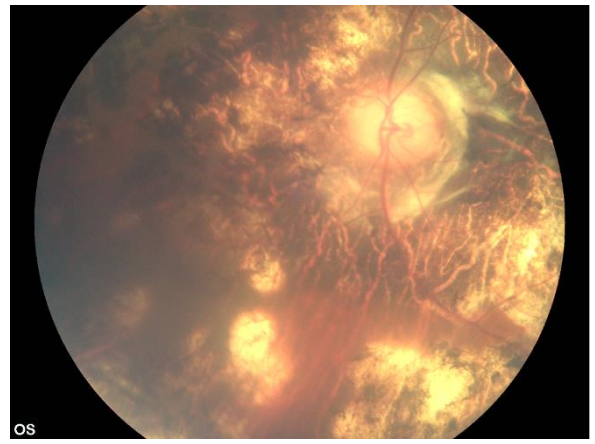


Figure 6. Fundus photos of the right and left eyes in 2020. Almost the entire retina shows a deep retinal lesion with a large amount of pigment.

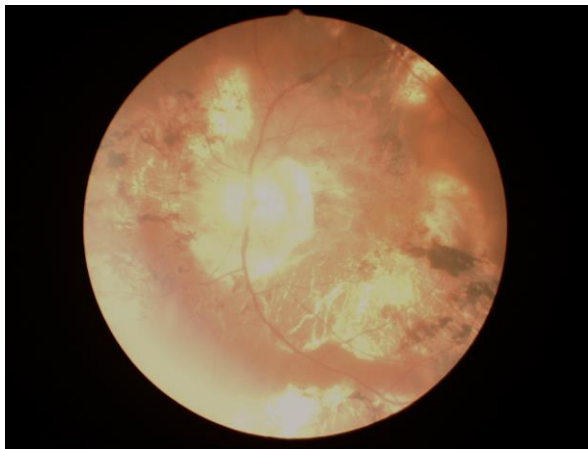

Figure 4. Fundus photos of the right and left eyes in 2014

The field of vision was sharply narrowed, practically absent (Figures 7,8). On the fundus, there were extensive pigmented areas.

Figure 7 and Figure 8. Field of vision of the right and left eye in 2020

Her next appointment was in 2020 (Figure 5, 6). The visual acuity of the right eye was 0.07, and that of the left eye was 0.04.

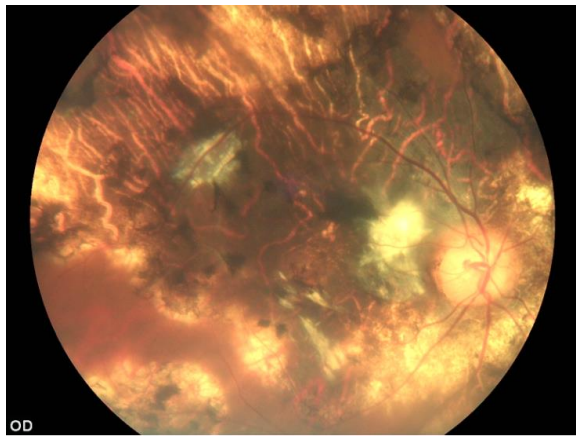
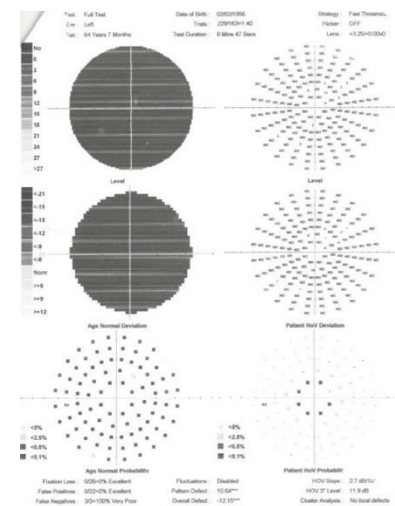
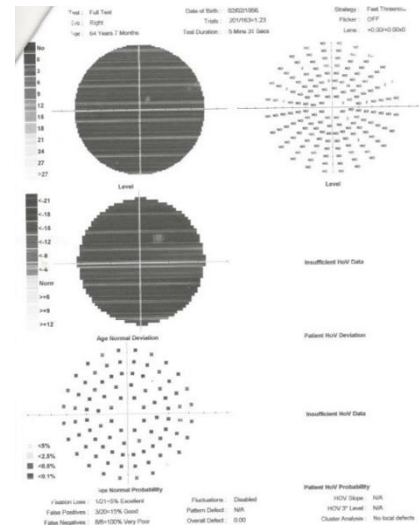


Figure 5. Fundus photos of the right and left eyes in 2020. Almost the entire retina shows a deep retinal lesion with a large amount of pigment.



An electroretinogram demonstrated mild depression of the scotopic dim flash in the right eye relative to the left eye (Figure 9).

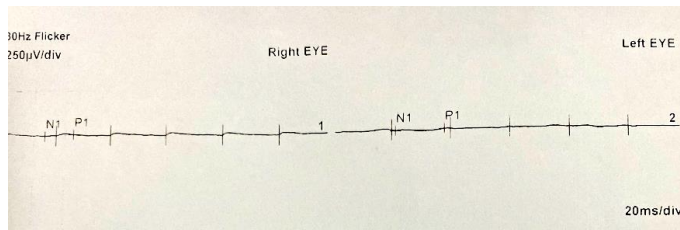


Figure 9. ERG both eyes. Multifocal Electroretinogram (mfERG) showed a loss of foveal peak in the both eyes with reduced parafoveal and normal perifoveal ring response in both eyes.

OCT showed disruption of the ellipsoid zone, loss of external limiting membrane and ellipsoid zone with corresponding to atrophic areas (Figure 10,11).

Since we had seen the positive effect of the combination of ampicillin and dexamethasone on inflammatory diseases of the retina, we did not give this patient parabalbar injections of dexamethasone but 3 injections of ceftriaxone 1 g intramuscularly and then dexamethasone 1.0 ml intravenously for 4 days. The visual acuity of both her eyes rose to 0.05.

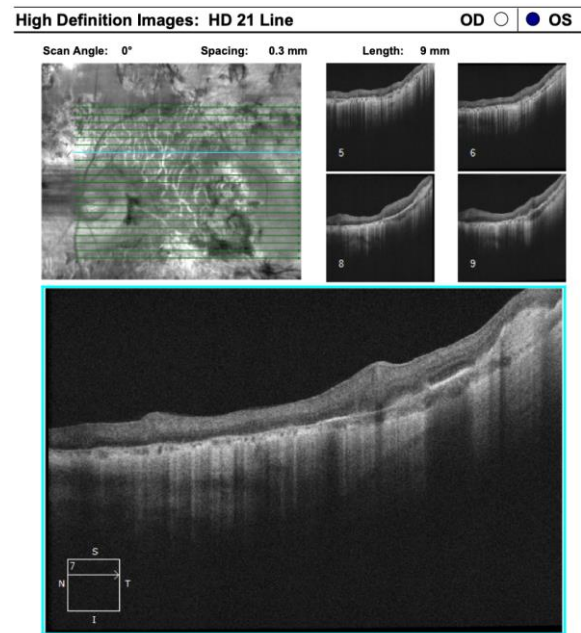


Figure 11. OCT of the right and left eye in 2020.

Discussion

In the present case, the patient did not have an autoimmune disease. Her vision began deteriorating in 1990. Despite the fact that an exact diagnosis was not made at that time, the parabalbar injections of dexamethasone led to a sharp improvement in visual acuity.

Her disease was characterized by periodic relapses, but dexamethasone helped well. At the initial visit, we gave her parabalbar injections for 8 days. In 2020, we used a combination of ceftriaxone and dexamethasone intravenously. However, these drugs were not administered at the same time. We started with an antibiotic and then switched to dexamethasone. Other authors noted a positive effect after prolonged intravitreal injection of Ozurdex (7).

At the beginning of AZOOR, changes in the retina are minimal, and blanching of the optic disc, characteristic of typical optic neuropathy, is absent. On the fundus, there are areas of depigmentation with a sharply defined border from normal tissue.

This case is of interest because we have observed its evolution for 30 years. Similar cases with such a long follow-up period have not been found in the literature.

This disease is characterized by sudden occurrence and is accompanied by periodic exacerbations. In the initial stage, changes in the fundus are minimal. Many authors testify to this (7), and it was also observed in our case.

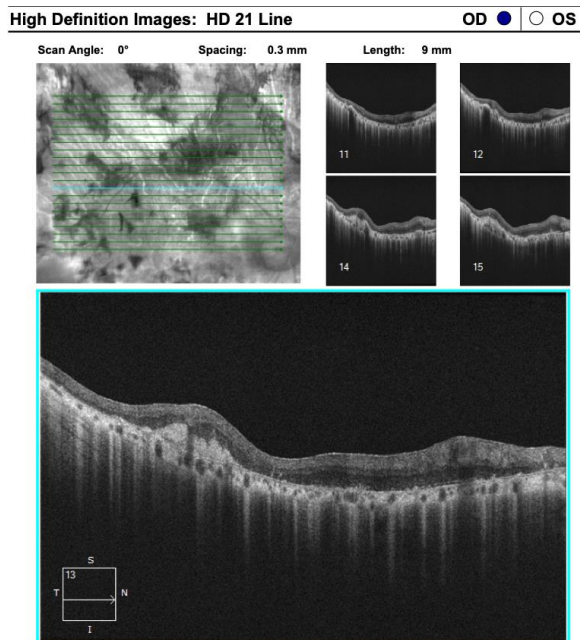


Figure 10. OCT of the right and left eye in 2020.

However, over time, these changes intensify, and a picture emerges that is similar to a total lesion of the retina. AZOOR is characterized by a narrowing of the boundaries of the field of view and changes in the ERG. Focal ERG is also reduced in diseases such as acute idiopathic blind spot enlargement syndrome (AIBSE) and multiple evanescent white dot syndrome (MEWDS) (8), but AZOOR is dramatically different in clinical presentation.

With AZOOR, these changes gradually progress; in addition to ERG deterioration, the other eye is also involved and eventually leads to severe pigment epithelial atrophy (9), including progressive loss of visual field over weeks or months, chronic photopsia, and late RPE atrophy.

Another characteristic of this disease is the strong positive effect of the systemic use of corticosteroids (10).

Some authors associate this disease with viral pathology and even try to treat it with antiviral drugs (11). Their effect is doubtful. Some authors have used anti-VEGF preparations intravitreally against the complication of choroidal neovascularization (12).

We have always treated the current patient with corticosteroids. Initially, these were parabolbar injections of dexamethasone; the last time, we used intramuscular treatment with ceftriaxone and then intravenous administration of dexamethasone. We used ceftriaxone on the assumption that the basis of retinal diseases is a disturbance of the microbiota of the genitourinary tract (13).

After all administration, there was a positive effect. We do not know whether the use of an antibiotic prior to the introduction of a systemic corticosteroid is more effective. In any case, the main treatment is systemic corticosteroids.

Conclusion

AZOOR occurs suddenly, most often in women. Initially, minimal retinal changes are characteristic of this disease, accompanied by clearly defined areas of retinal dystrophy. There is a local narrowing of the visual field and a decrease in the amplitude of the ERG.

The difference between this disease and other diseases accompanied by a decrease in ERG is the good response to systemic corticosteroids (parabolbar or intravenous dexamethasone).

This disease is characterized by periodic exacerbations and gradual progression. After 30 years of observation of the present case, there was a significant decrease in VA and the visual field and almost total retinal dystrophy, with the reduced ERG.

Conflict of interests

The author declares that there is no conflict of interest.

Data availability statement

The data that support the findings of this study are available from the corresponding author upon reasonable request.

Funding

None.

Study association

This study is not associated with any thesis or dissertation work.

References

1. Gass JD. Acute zonal occult outer retinopathy. Donders Lecture: The Netherlands Ophthalmological Society, Maastricht, Holland, June 19, 1992. *J Clin Neuroophthalmol.* 1993 Jun;13(2):79-97. PMID: 8340485.
2. Rishi P., Rishi E. Bilateral acute zonal occult outer retinopathy (AZOOR) in a young adult Indian male. *GMS Ophthalmology Cases*, 04 Apr 2019, 9:Doc11DOI: 10.3205/oc000100
3. Arai M, Nao-i N, Sawada A, Hayashida T. Multifocal electroretinogram indicates visual field loss in acute zonal occult outer retinopathy. *Am J Ophthalmol.* 1998 Sep;126(3):466-9. doi: 10.1016/s0002-9394(98)00117-2. PMID: 9744389.
4. Browning AC, Gupta R, Barber C, Lim CS & Amoaku WM (2003): The multifocal electroretinogram in acute macular neuroretinopathy. *Arch Ophthalmol* 121: 1506–1507. DOI: 10.1001/archophth.121.10.1506
5. Gass JD, Agarwal A & Scott IU (2002): Acute zonal occult outer retinopathy: a long-term follow-up study. *Am J Ophthalmol* 2002 Sep;134: 329–339 DOI: 10.1016/s0002-9394(02)01640-9;
6. Carrasco L, Ramos M, Galisteo R, Pisa D, Fresno M & Gonzalez ME: Isolation of *Candida famata* from a patient with acute zonal occult outer retinopathy. *J Clin Microbiol* 43: 635–640. doi: 10.1128/JCM.43.2.635-640.2005
7. Kuo YC, Chen N, Tsai RK. Acute Zonal Occult Outer Retinopathy (AZOOR): a case report of vision improvement after intravitreal injection of Ozurdex. *BMC Ophthalmol.* 2017 Dec 6;17(1):236. doi: 10.1186/s12886-017-0638-5. PMID: 29207977; PMCID: PMC5718015.
8. Inagawa S, Onda M, Miyase T, et al. Multiple evanescent white dot syndrome following vaccination for COVID-19: A case report. *Medicine (Baltimore).* 2022;101(2):e28582. doi:10.1097/MD.00000000000028582
9. Volpe NJ, Rizzo JF, Lessell S. Acute idiopathic blind spot enlargement syndrome. A review of 27 new cases. *Arch Ophthalmol.* 2001;119(1):59-63. doi:10-1001/pubs.Ophthalmol.-ISSN-0003-9950-119-1-ecs90241
10. Yang C.H., Yang C.M. Systemic Corticosteroids Therapy in the Management of Acute Zonal Occult Outer Retinopathy. *Journal of Ophthalmology*, vol. 2015, Article ID 793026, 6 pages, 2015. <https://doi.org/10.1155/2015/793026>

11.Mahajan V.B., Stone E.M. Patients with an Acute Zonal Occult Outer Retinopathy-like Illness Rapidly Improve with Valacyclovir Treatment. *Am J Ophthalmol.* 2010 Oct; 150(4): 511–518.doi: 10.1016/j.ajo.2010.05.024

12.Introini U, Casalino G, Dhrami-Gavazi E, Mukkamala SK, Mrejen S, Schubert H, Cohen SY, Azzolini C, Bandello F, Chang S, Yannuzzi LA. Clinical course of acute zonal occult outer retinopathy complicated by choroidal neovascularization. *Int J Retina Vitreous.* 2018 Aug 29;4:32. doi: 10.1186/s40942-018-0134-y. PMID: 30181904; PMCID: PMC6114516.

13.Hajiyev R.V. On the pathogenesis of diabetic retinopathy, damage to Mueller cells, diseases of opponents, and inflammation: a review. *Ophthalmology Cases Hypotheses.* 2021;02(02):14-18.

How to cite this article: Hajiyev R.V. Acute zonal occult outer retinopathy (AZOOR) progression: 30-year follow-up of a clinical case. *Ophthalmology Cases & Hypotheses.* 2022;03(01)6 :4-9. DOI:10.30546/2788-516X.2022.3.1.4